



INTRODUCTION

Laser interstitial thermal therapy (LITT) is an effective treatment for regrowing lesions after previous radiosurgery to brain metastases, typically resulting in decreased perilesional edema within weeks after surgery followed by delayed reduction in lesion size. We have anecdotally observed that patients on immunotherapy (IT) at time of LITT may exhibit a delayed edema resolution response to laser ablation. A such, we sought to determine whether IT may influence the response of lesion size and perilesional edema to LITT.

METHODS

Post-operative imaging for cases of LITT, performed by the senior author between June 2012 and July 2019, for regrowing lesions after prior radiosurgery for brain metastases were retrospectively reviewed. The IT group was defined as any patient receiving IT treatment within 3 months of the date of LITT. Post-operative MRIs obtained at serial time points after surgery (2 weeks, 6 weeks, 3 months, 6 months, and 12 months) were reviewed for treatment response to LITT, defined as a change in surrounding edema on T2 FLAIR images and change of lesion size on T1-weighted post-contrast images. MRIs were reviewed by a single observer and in equivocal cases, radiology reports were referenced to determine changes in lesion size and edema.

CASE ILLUSTRATION 1 - LITT on non-immunotherapy

A 62 year-old male with metastatic non-small cell lung cancer on systemic therapy with erlotinib underwent LITT for an asymptomatic but growing right occipital lesion previously treated with stereotactic radiosurgery (Figure 1A, B). He recovered uneventfully and MRI at 2 weeks post-operatively showed similar lesion size but decreased perilesional edema (Figure 1C, D). Both continued to decrease on serial imaging and MRI at 12 months showed near complete resolution of the lesion (Figure 1E, F).

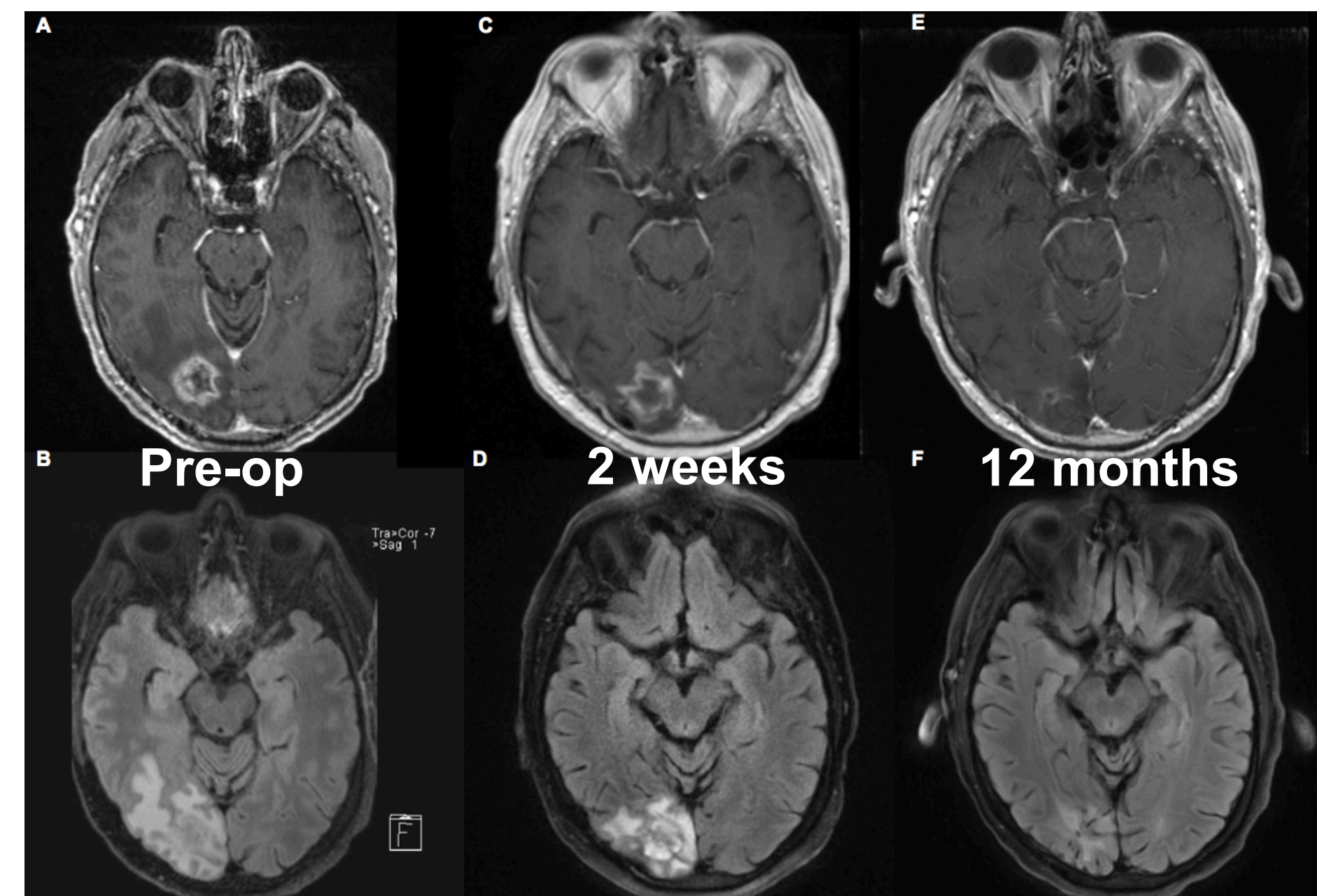


Figure 1. Pre-operative (A) T1 post-contrast and (B) T2 FLAIR MRI. 2 week follow-up (C) T1 post-contrast and (D) T2 FLAIR MRI. 12 month follow-up (E) T1 post-contrast and (F) T2 FLAIR MRI.

CASE ILLUSTRATION 2 - LITT on immunotherapy

A 59 year-old male with metastatic non-small cell lung cancer on ipilimumab and nivolumab immunotherapies underwent LITT for a symptomatic regrowing left cerebellar lesion that had previously been treated with stereotactic radiosurgery (Figure 2A, B). He recovered, albeit with persistent dizziness and gait instability, and immunotherapy was resumed shortly after LITT. MRI at 2 weeks post-operatively showed increased lesion size and perilesional edema, which was not unexpected (Figure 2C, D). However, continued serial imaging demonstrated persistently larger lesion size and edema at 3 and 6 months (Figure 2E, F), compared to pre-operative baseline. Immunotherapy was subsequently stopped and at 12 month follow-up, imaging showed a significantly regressed lesion and edema (Figure 2G, H). He was still experiencing mild coordination difficulty, but his gait had greatly improved.

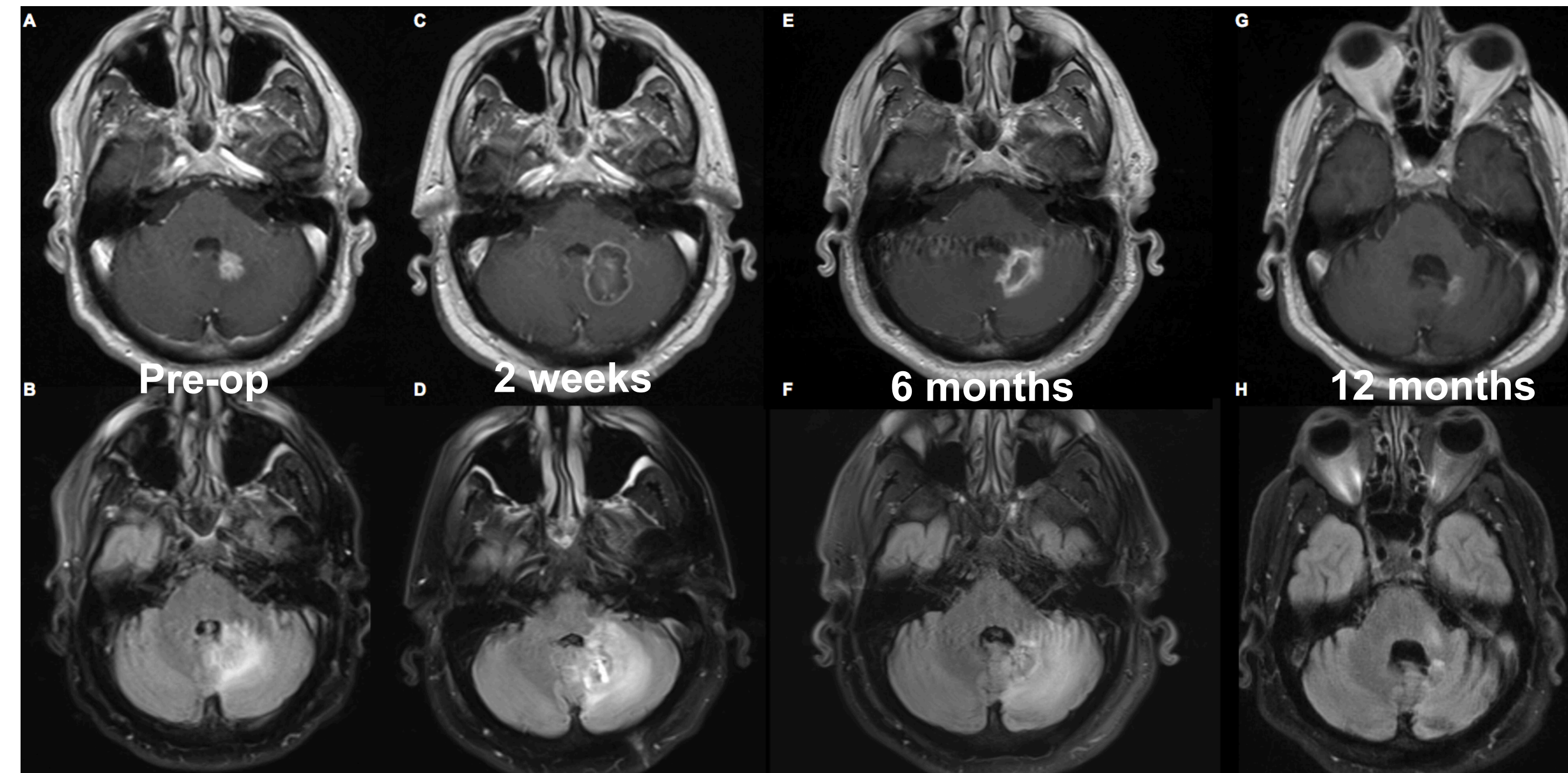
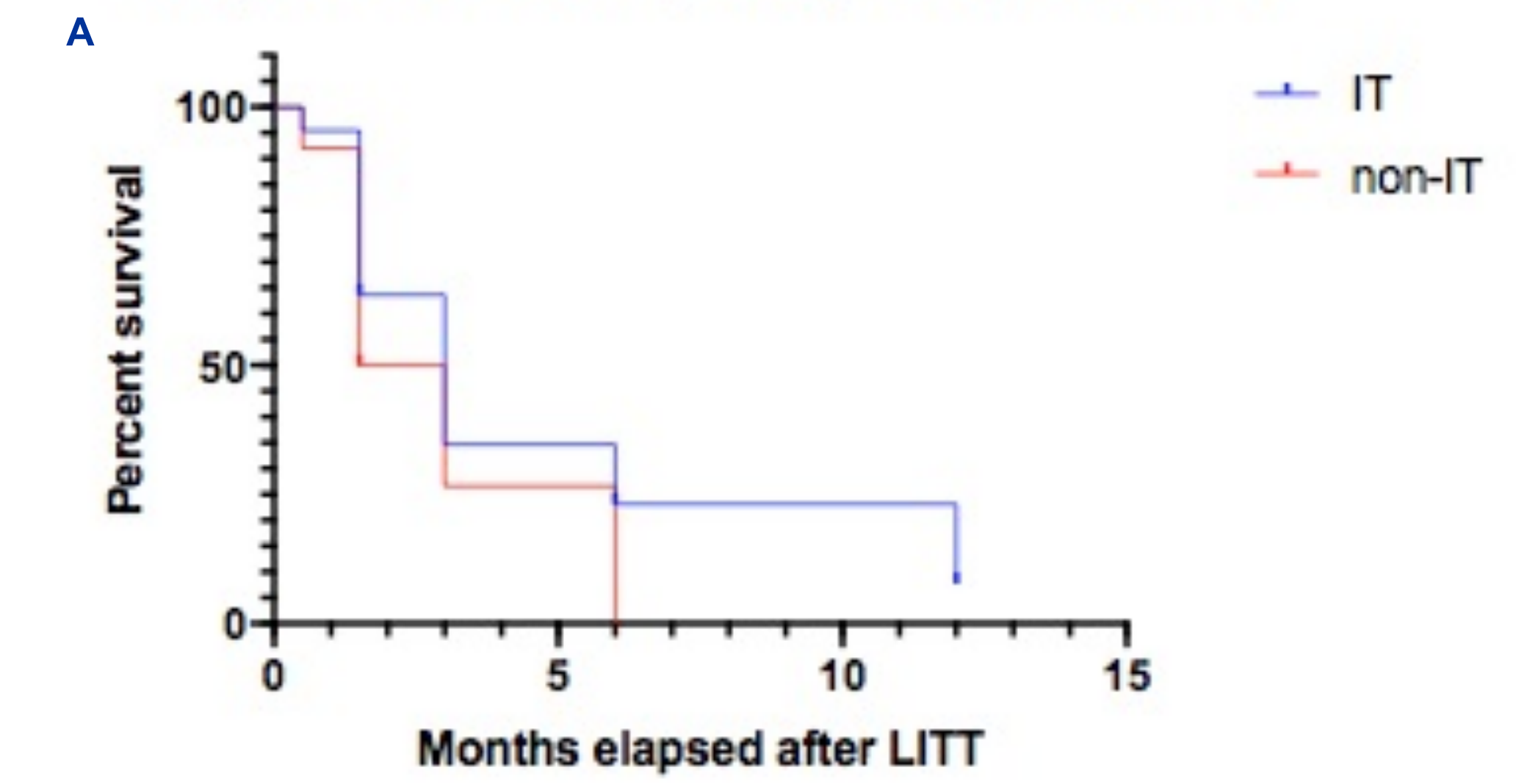


Figure 2. Pre-operative (A) T1 post-contrast and (B) T2 FLAIR MRI. 2 week follow-up (C) T1 post-contrast and (D) T2 FLAIR MRI. 6 month follow-up (E) T1 post-contrast and (F) T2 FLAIR MRI. 12 month follow-up (G) T1 post-contrast and (H) T2 FLAIR MRI.

RESULTS

Out of 60 ablated lesions, 22 were in the IT group and 38 were in the non-IT group. There were no differences in distribution of original cancer pathology (IT: 9 melanoma, 8 lung, 5 other, non-IT: 6 melanoma, 20 lung, 12 other; $p > 0.05$). Time to lesion size response on T1-weighted post-contrast MRI neared but did not reach statistical significance between the IT and non-IT groups: median 3.0 versus 2.25 months (HR 1.5, 0.8-2.5, 95% CI, $p = 0.08$), respectively (Figure 3A). However, time to reduction of perilesional edema on T2-weighted MRI was significantly longer in the IT group, compared to the non-IT group: median 2.25 versus 1.5 months (HR 1.5, 0.9-2.5, 95% CI, $p = 0.04$), respectively (Figure 3B).

Response on T1-weighted post-contrast MRI



Response on T2-weighted MRI

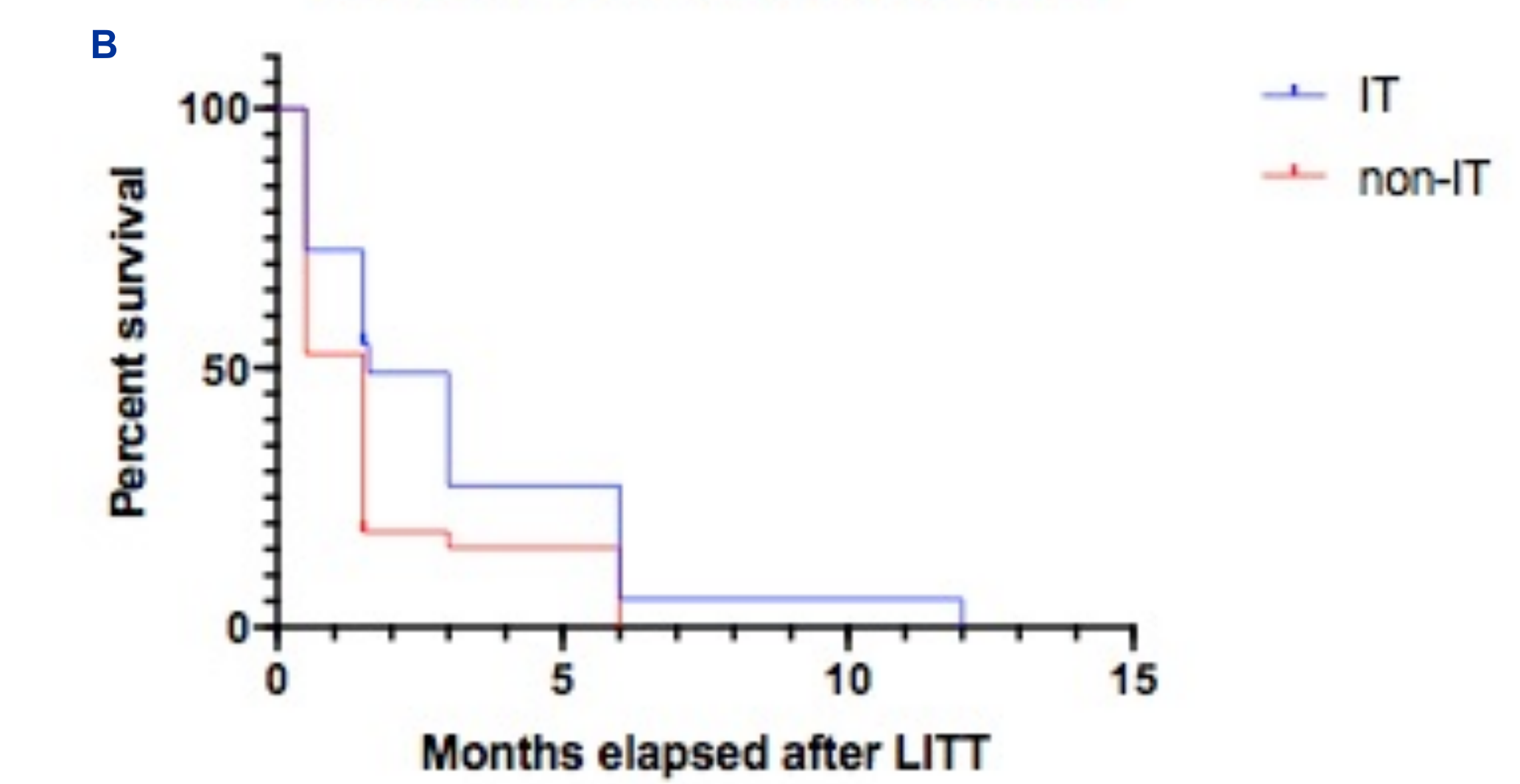


Figure 3. Kaplan-Meier curves comparing (A) time to lesion size response on T1-weighted MRI and (B) time to reduction of perilesional edema on T2-weighted FLAIR MRI among patients in the IT vs non-IT groups.

CONCLUSION

These data suggest that treatment with IT around the time of LITT may lead to a delayed edema reduction on MRI after LITT. We hypothesize that IT may enhance normal immune-mediated mechanisms thus increasing perilesional inflammation after LITT. Further studies are needed to corroborate our observations and explore the underlying pathophysiology.

REFERENCES

- Torres-Reveron J, Tomasiwicz HC, Shetty A, Amankulor NM, Chiang VL. Stereotactic laser induced thermotherapy (LITT): a novel treatment for brain lesions regrowing after radiosurgery. *J Neurooncol.* 2013;113(3):495-503.
- Hong CS, Deng D, Vera A, Chiang VL. Laser-interstitial thermal therapy compared to craniotomy for treatment of radiation necrosis or recurrent tumor in brain metastases failing radiosurgery. *J Neurooncol.* 2019;142(2):309-317.
- Hong CS, Beckta JM, Kundishora AJ, Elsamadicy AA, Chiang VL. Laser interstitial thermal therapy for treatment of cerebral radiation necrosis. *Int J Hyperthermia.* 2020;37(2):68-76.
- Ahluwalia M, Barnett GH, Deng D, et al. Laser ablation after stereotactic radiosurgery: a multicenter prospective study in patients with metastatic brain tumors and radiation necrosis. *J Neurosurg.* 2018;130(3):804-811.

