

Pulmonary Arteriovenous Malformations. Reperfusion after Embolotherapy; Vascular Plugs, Coils or both.

Authors: F. Casero Navarro, Q. Ordi I Camprubi, D.A. León Guevara, E. Alba Rey, J. Valcarcel José, J.R. Joudanin Seijo, J. Ribas Sola, A. Riera Mestre. Interventional radiology unity, Hospital Universitari de Bellvitge. Hospitalet del Llobregat.Barcelona.ES.

Purpose.

Embolization of pulmonary arteriovenous malformations (PAVMs) in patients affected with hereditary hemorrhagic telangiectasia has a high re-canalization/reperfusion rate. Our objective is to describe and evaluate our repermeabilization rate of the PAVMs treated with different embolic agents.

Material and Methods.

We retrospectively reviewed a total of 26 patients with 43 PAVMs treated between May 2012-Dec 2018, in our hospital. Age and sex were recorded. PAVM's with high shunt diagnosed on echocardiogram / bubble (≥ 2 degree / bubble scale) was the main indication for treatment. We also included 2 patients whose treatment was performed in 2 delayed procedures within 3 month, due to complex fistula.

Patients were registered in different groups according to whether they were treated with coils, vascular plugs or both. Re-canalization/reperfusion of the treated PAVMs (defined as the presence of contrast within the aneurysmal sac from recanalization of vessel occluded or reperfusion from a different one) was evaluated with Computed Tomography Angiography performed one year after percutaneous treatment. Complications were recorded.

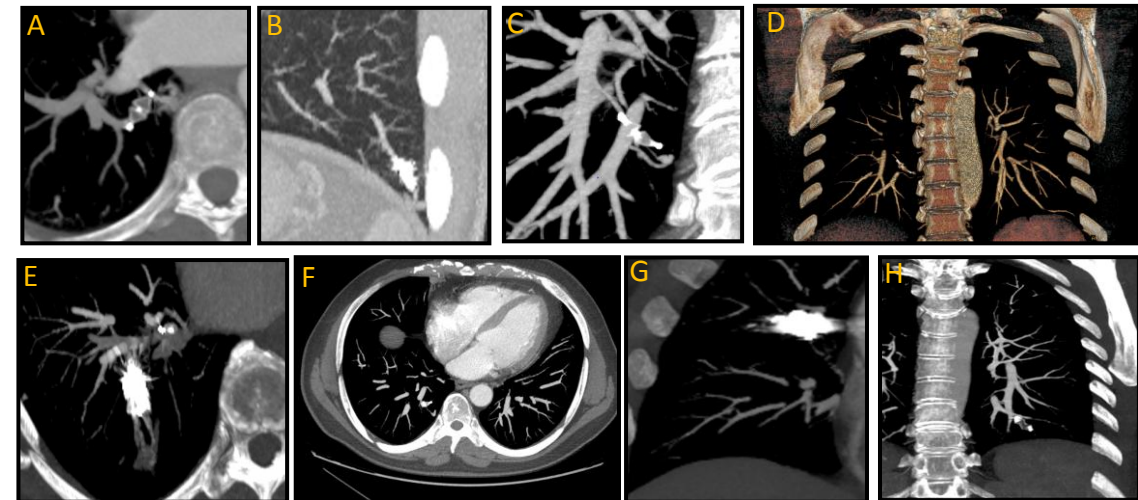
Results.

26 patients were treated (17 women, 9 men; mean age, 45 years range 16-72 years) with a total of 43 PAVMs (39 simple and 4 complex). 7 PAVMs were treated with coils, 26 PAVMs were treated with Vascular Plugs and 10 PAVMs were treated with Coils + Vascular Plugs.

The recanalization rate registered in the CT-control-year was: Coils 4/7 (57,14%), Vascular Plugs 12/26 (46.15%); Coils + Vascular Plugs 1/10 (10%). Of the PAVMs that presented recanalization-reperfusion only 1 PAVMs (1/17 0.05%) needed reembolization in a second time, due to an increase in the degree of shunt and the presence of dyspnea at moderate efforts. Three episodes of minor hemoptysis were presented during the procedure and one episode of self-limited neurological focality.

Conclusions.

The re-canalization / reperfusion rates obtained have been those expected within the literature, except for the group of patients treated only with Vascular Plugs, which presented a repermeabilization greater than observed. In our cases the lowest repermeabilization rate was obtained with the combined treatment (Vascular Plugs + Coils). The reembolization rate of PAVMs is very low, so percutaneous treatment is considered an effective and safe intervention although there may be complications.



Different examples of embolized PAVMs.

Figure A, B, C, D, E, F: Examples of recanalization / reperfusion.

G,H: PAVMs treated with coils + amplatzer and only coils showing no evidence of recanalization.